

> Experience feedback

Focus on an event notified to ASN through vigie-radiotherapie.fr

May 2014

Avoiding a positioning error during kV-kV imaging

Positioning of the patient during treatment under the accelerator can be checked periodically using an imaging system capturing images in kilovoltage mode (kV-kV), by locating bone structures. Positioning errors may be associated with an error identifying a bone marker.

5 patient positioning errors associated with incorrect identification of a vertebral marker on a kV image were notified to ASN between June 2013 and February 2014.

One of the notifying centres shares its analysis and measures for avoiding positioning errors during kV-kV imaging

> The significant event in brief

Patient treated for a bronchial tumour with oblique fields at a total dose of 40 Gy (20 sessions of 2 Gy).

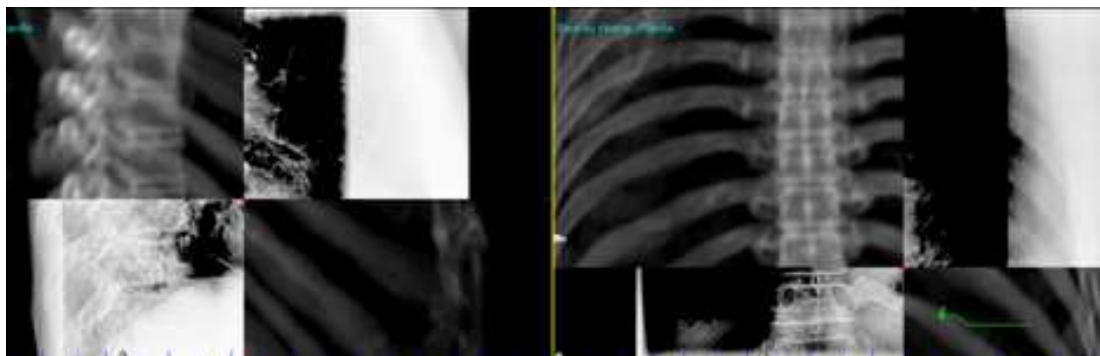
In addition to an MV image on day 0 and then weekly, a daily check of patient positioning is made by kV-kV imaging (orthogonal images).

Repositioning is carried out by checking the alignment of the spinous processes (see picture below).

Daily kV-kV images are approved by a radiation oncologist at least twice a week.

During the first 6 to 10 sessions, a positioning error of 2.5 cm occurred longitudinally (head to feet).

The error was detected by a radiographer during the 10th session.



Verification of the positioning of a patient through the registration of a DRR and a kV image (side view (left) and anterior-posterior view (right))

> Analysis of causes

Organisational and human factors

- > Confusion between anatomical features (vertebrae)
- > Time factor (decision-making and analysis)
- > Number factor (staff rotation, number of images to be analysed by the radiation oncologist)
- > Influence of displacements from previous days
- > Mutual trust between radiation oncologist and radiographer

Technical factors

- > Difficulties analysing thoracic images
 - Equipment: limited size of X-ray detector
 - Image acquisition and reconstruction parameters:
 - Software: filter, image reconstruction
 - X-ray tube constants: pre-defined protocol, collimation

> Analysis of barriers

Barriers that functioned

- > Vigilance of radiographers: displacement for the day in opposing direction to that used the day before

Barriers that did not function

- > Reading of images by radiation oncologists

> Useful actions identified to avoid this error occurring

The solutions presented below have been implemented by the centre that had to deal with the event.

They are in no way restrictive and should only be implemented if they appear relevant and appropriate to a department's organisation.

1. Consideration of procedures for reading kV images by radiation oncologists : certain locations (thoracic) need more time and attention.
2. Systematic test to identify specific structures on the kV images.
3. Acquisition of shifted kV images only to look for features to aid positioning. kV image on the axis is essential to validate the positioning.
4. If in doubt about reading the image, call the referent radiation oncologist or, if not available, a colleague. Leave a written outline on the image. Don't hesitate to repeat an MV image to locate known features (e.g. the carina).
5. If the displacements are inconsistent over 3 consecutive sessions, the patient file must be reviewed.
6. If the displacement is more than 5 mm, check patient positioning in the treatment room, repeat acquisition of an image. If the displacement persists, call the physician.
7. Optimisation of image acquisition parameters based on the location (with participation by a radiology resident).